Araştırma Makalesi / *Research Article*

İzmir Eğitim ve Araştırma Hastanesi Tıp Dergisi (Medical Journal of İzmir Hospital) 24 (4): 283-288, 2020

EVALUATION OF THE RESULTS OF HYPERACUTE SURGERY FOR INTRACEREBRAL HEMATOMAS 4 CM OR MORE IN SIZE ORGINATING FROM BASAL GANGLIA

BAZAL GANGLİON KAYNAKLI 4 CM VE ÜZERİ İNTRASEREBRAL HEMATOMLARDA UYGULANAN HİPERAKUT CERRAHİNİN SONUÇLARININ DEĞERLENDİRİLMESİ

Ümit KOCAMAN[1] Hakan YILMAZ[2]

[1]İzmir Çiğli Bölge Eğitim Hastanesi, Beyin ve Sinir Cerrahisi Kliniği, İzmir, Türkiye
[2]S.B.Ü. İzmir Bozyaka Eğitim ve Araştırma Hastanesi, Beyin ve Sinir Cerrahisi Kliniği, İzmir, Türkiye

Anahtar Sözcükler: Intraserebral hematom, cerrahi, bazal ganglion.
Keywords: Intracerebral hematoma, surgery, basal ganglia.

Yazının alınma tarihi: 28.06.2020 *Yazının Kabul tarihi: 23.10.2020* *Online basım tarihi: 30.12.2020*

ÖZ

Giriş: *Supratentoryal bölgede bazal ganglion kaynaklı 4 cm ve üzerinde spontan intraserebral hematom saptanarak 2 saat içinde kraniyotomi ile hematom drenajı ve dekompresyon yapılan hastalardaki cerrahi sonuçlarımızı sunmak istiyoruz.*

Gereç ve Yöntem: *2016-2020 yılları arasında kliniğimizde sadece bazal ganglion bölgesinde ya da bazal gangliondan lober alana uzanım gösteren en az 4 cm ve üzeri intraserebral hematom sebebiyle acil cerrahi uygulanan hastalar retrospektif olarak değerlendirmeye alınmıştır. Hastalar demografik özellikler, cerrahi öncesi Glasgow koma skoru(GKS), intraventriküler hematom varlığı, lokalizasyon, intraserebral hematom skoru, hidrosefali varlığı ve Glasgow outcome skoru (GOS) açısından değerlendirilmiştir.*

Bulgular: *Yirmibir hastanın 11'i(%52.4) kadın, 10'u (%47.6) erkekti. Başvuru GKS 6(%28.6) hastada 4, 2(%9.5) hastada 5, 4(%19.0) hastada 6, 2(%9.5) hastada 7, 3(%14.2) hastada 8, 1 (%4.7) hastada 9, 2 (%9.5) hastada 11ve 1 (%4.7) hastada 12' idi. Kanama tipi 9 hastada (%42.8) bazal ganglion kanaması ve 12 hastada (%57.1) lobar + bazal ganglion kanamasıydı.GOS 21 (% 100) hastada 1 olarak sonuçlandı.*

Sonuç: *Bazal ganglion kökenli cerrahi boyuttaki kanamalarda, cerrahi tedavinin yararı tartışmalıdır.*

SUMMARY

Introduction: *We would like to present our surgical results in patients who were found to have a spontaneous intracerebral hematoma 4 cm or more in size in supratentorial region originating from basal ganglia and underwent hematoma drainage and decompression with craniotomy within 2 hours.*

Material and methods: *Patients who underwent emergency surgery between 2016 and 2020 at our clinic for an intracerebral hematoma 4 cm or more in size only in basal ganglia area or extending into lobar area from basal ganglia were retrospectively evaluated. The patients were assessed in terms of demographic characteristics, preoperative Glasgow Coma Score (GCS), intraventricular hematoma presence and localization, intracerebral hematoma score, hydrocephalus presence and Glasgow outcome score (GOS).*

Results:*Of the 21 patients, 11(52.4%) were female and 10(47.6%) were male. Admission GCS was 4 in 6 (28.6%) patients, 5 in 2(9.5%) patient, 6 in 4(19,0%) patients, 7 in 2(9.5%) patients, 8 in 3 (14.2%) patients,*

9(4.7%) in 1 patient, 11 in 2(9.5%) patients and 12 in 1(4.7%) patient.The hemorrhage type was basal ganglion hemorrhage in 9(42.8%) patients , and lobar + basal ganglion hemorrhage in 12(57.1%) patients.The GOS was 1 in 21(100%) patients.

Conclusion:*The benefit of surgical treatment is controversial in surgical-sized hematomas of basal ganglia origin.*

INTRODUCTION

Spontaneous intracerebral hematomas make up 10-15% of all stroke cases. The mortality rate is generally accepted to be over 40% in one year. The functional improvement ratio after a hematoma develops is 16.7-24.6%. The theoretical benefits of early hematoma drainage are recognized but there is no consensus on the treatment. The general tendency is to use surgical methods for superficial lobar hematomas and a conservative approach for deep lesions. However, performing surgery for hematomas 4 cm or more in size seems to be the main criterion for the supratentorial region (1-3).

METHODS

Patients who underwent surgery for intracerebral hematoma at our clinic between 2016 and 2020 were investigated retrospectively. Local ethics committee approval was received for this study (Izmir Cigli Region Research Hospital scientific committee-22.04.2020-6913).Cases who presented to the emergency department with an intracerebral hematoma 4 cm or more in size originating frombasal ganglia region and underwent hematoma drainage with craniotomy within 2 hours were evaluated. Cranial CT angiography or cranial MR angiography was performed in cases with a suspected vascular anomaly before the surgery. The patients were evaluated in terms of age, gender, preoperative Glasgow coma score, intraventricular hematoma presence, localization, intracerebral hematoma score, massive hemorrhage status, hydrocephalus presence and the Glasgow outcome score. Patients with anticoagulant use and hypertension were indicated as a proportion. Preoperatively, 10 mg vitamin K was administered intravenously and 2 units of fresh frozen plasma was started and then continued preoperatively for patients with a history of anticoagulant use. The localization was classified as lobar, basal ganglion or both. Massive hemorrhage was accepted as hemorrhage covering half or more of a hemisphere.

Statistical analysis

All statistical analyses were performed using the Statistical Package for the Social Sciences (SPSS) version 22.0. Continuous variables were expressed as means.

RESULTS

Of the 21 patients, 11(52.4%) were female and 10(47.6%) were male. The mean age was 76.6 (61-94) years. There was a history of hypertension in 16(76.1%) patients and of anticoagulant/antiaggregant treatment in 6(28.5%) patients. Admission GCS was 4 in 6 (28.6%) patients, 5 in 2(9.5%) patient, 6 in 4(19,0%) patients, 7 in 2(9.5%) patients, 8 in 3 (14.2%) patients, 9(4.7%) in 1 patient, 11 in 2(9.5%) patients and 12 in 1(4.7%) patient.

An intraventricular hematoma was found in 18(85.7%) patients. The hemorrhage type was basal ganglion hemorrhage in 9(42.8%) patients, and lobar + basal ganglion hemorrhage in 12(57.1%) patients. Hematoma is on the left side in 11(52.3%) patients and on the right side in 10(47.6%) patients.

The intracerebral hematoma score (ICHS) was 2 in 3(14.2%) patients, 3 in 6(28.5%) patients, 4 in 10(47.6%) patients, 5 in 2(9.5%) patients. Massive hemorrhage was found in 8(38.0%) patients. Hydrocephaly was present in 5(23.8%) patients. These patients underwent external ventricular drainage placement during the craniotomy session.

Postoperatively increased intracranial pressure have controlled by correcting the patient's position, temperature, drainage of CSF via external drainage, induced hypocapnea (hyperventilation; paCO2 < 35 mmHg), hyperosmolartherapy (mannitol, hypertonicsaline) and induced arterial hypertension (CPP concept). The GOS was 1 in 21(100%) patients.Death was the end result in 21 of the 21 patients who underwent surgery for spontaneous intracerebral hematoma (a mortality rate of 100%).

Demographic characteristics of the patients, intracerebral hemorrhage characteristics, hemorrhage scores, preoperative GCS scores and postoperative GOS are summarized in Table 1.

Among the presented cases, the surgery was performed for lobar hemorrhage+basal ganglion hemorrhage in 1 case (Figure 1) and basal ganglion hemorrhage in 1 case (Figure 2).

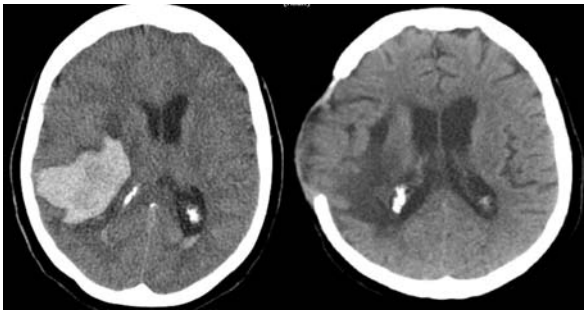

Figure 1. Preoperative and postoperative brain tomography of the patient who was operated due to lobar + basal ganglion hemorrhage.

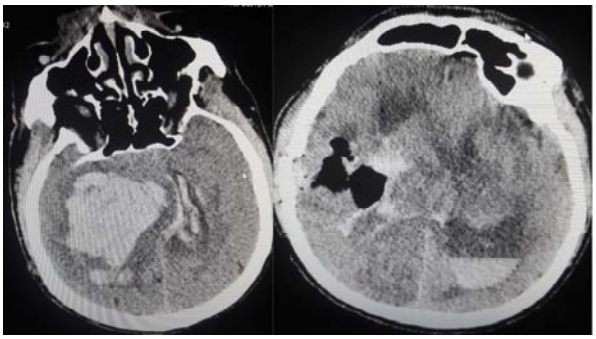

Figure 2. Preoperative and postoperative brain tomography of a patient who was operated due to basal ganglion hemorrhage.

DISCUSSION

Supratentorial intracerebral hematomas are especially common in the senile population. The disorder has a high mortality rate. Conservative and surgical approaches are recommended for its treatment and operating on intracerebral hematomas 4 cm or larger in size has gained widespread acceptance for the supratentorial region (1,4).

Table 1. Patients who were found to have spontaneous intracerebral hematoma and underwent hematoma drainage and decompression with craniotomy within 2 hours.

No	Age	Sex	Preop GCS	IVH	Loc		ICH-Score	Massive	HDS	GOS
1	68	M	4	+	L+BG	R	4	+	-	1-Ex
2	78	F	5	+	L+BG	L	3	+	+	1-Ex
3	74	M	8	-	L+BG	L	2	-	-	1-Ex
4	84	F	4	+	BG	R	5	-	-	1-Ex
5	61	M	6	+	BG	L	3	-	-	1-Ex
6	82	F	11	+	BG	R	4	-	-	1-Ex
7	72	M	4	+	L+BG	L	4	+	+	1-Ex
8	64	F	6	+	BG	L	3	-	-	1-Ex
9	82	F	6	+	L+BG	R	4	+	-	1-Ex
10	66	F	11	-	BG	L	2	-	-	1-Ex
11	94	M	4	+	L+BG	R	5	+	-	1-Ex
12	69	F	8	+	BG	R	3	-	-	1-Ex
13	84	M	12	+	BG	L	4	-	-	1-Ex
14	78	M	4	+	L+BG	L	4	+	+	1-Ex
15	86	F	5	+	L+BG	R	4	+	-	1-Ex
16	72	F	7	+	BG	R	3	-	-	1-Ex
17	67	M	8	+	L+BG	L	3	-	-	1-Ex
18	88	F	7	+	L+BG	R	4	-	-	1-Ex
19	77	M	4	+	BG	R	4	+	+	1-Ex
20	90	F	6	+	L+BG	L	4	-	-	1-Ex
21	73	M	9	_	L+BG	L	2	-	+	1-Ex

IVH: Intraventricularhematoma, Loc:Localization, ICH score: Intracerebralhematomascore, Massive: Massivehematoma, HDS: Hydrocephalus, L: Left, R: Right

Cordonnier et al. have described spontaneous intracerebral hematomas as life-threatening disorders with a poor prognosis, global importance, and few proven treatment methods (5). We find their article striking in terms of the significance of the threat on human life. Survival and recovery are related to the location of the hematoma, mass effect, intracranial pressure, cerebral edema and prolonged neurological dysfunction. One of our aims in publishing the current study was similarly to emphasize the high mortality rate as 21 of our 21 patients operated for intracerebral hematoma died. These patients had basal ganglion hemorrhage or basal ganglion + lobar hemorrhage.

Seppo et al. treated 52 patients surgically or conservatively in their prospective randomized study. Patients with poor consciousness and severe neurological deficits were also included in this study. The mean mortality rate was 42%. The mortality rate was 38% in the 26 patients treated conservatively and 46% in the 26 patients treated surgically. The mortality-decreasing effect of surgery was found to be statistically significant in those with a GCS of 7 to 10 (6). The mortality rate was also low in patients treated surgically in their study and this was significantly different from our study.

Zuccarello et al. reported the rate of postoperative GOS of 3 or higher as 56% in supratentorial intracerebral hematomas that had undergone early surgery. The treatment was surgical in 9 patients and conservative in 11 patients. No significant difference was found between the two treatment forms in the first 3 months in terms of GOS. The same result is also valid for the abovementioned study of Sepoa et al. (6,7).

However, Fernandes et al. reported in their meta-analysis on mortality and addiction after intracerebral hematoma surgery that the tendency for these two conditions increased postoperatively and resulted in a rate of 95%. It must be mentioned that it was conducted by a survey of the 1966-1999 period and includes different preoperative and postoperative conditions compared to today (8).

Hematomas of this size are often accompanied by midline shift and advanced hemispheric edema. Godoy DA et al. reviewed 6 different publications with 381 patients and ICP was found to be above 20 mmHg in 67% of the subjects. If intraventricular hematoma is present, the possibility of developing acute hydrocephalus should always be kept in mind. Patients usually are in stupor or coma when they are evaluated at the emergency department. All of the above-mentioned clinical conditions pave the way for a surgical indication. Prompts surgery is then performed considering that it may provide an improvement in the condition of the patient (9).

Chen et al. published articles with the main theme of the predictors of surgical intervention in patients with spontaneous intracerebral hemorrhage. The independent factors of young age, good baseline neurological function, extensive intracerebral hemorrhage, and infratentorial hematoma were predictors for preferring surgical intervention (10). Luzzi et al. reported that surgery should be preferred in patients with a GCS score between 5-12 and hematoma volume over 30 ml. They suggested a timing of 7-24 hours after the incident (11).

The incidence of hypertension, amyloid angiopathy, anticoagulant/antiaggregant use and intracerebral hematoma (ICH) due to vascular pathologies are usually high in the senile population. Concomitant systemic diseases and especially hypertension and cardiac and pulmonary pathologiesplay a role in the morbidity and mortality. On the other hand, ICH usually develops due to an underlying pathology such as arteriovenous malformation/fistula, aneurysm or tumor. We investigated vascular anomalies with CT angiography or MR angiography as required in our study cases.

The age of the patient, preoperative GCS score, size and mass effect of the hematoma, comorbid disorders and anticoagulant use influence the prognosis in supratentorial intracerebral hematomas. Large case series with individual evaluation of all these factors may elucidate the matter. However, we have observed that the most important factor in the surgical decision is the hematoma size. Standardization was therefore based on hematoma size in our series. A total of 21 cases underwent surgical decompression due to intracerebral hematoma of

4 cm or more and hematoma drainage was performed with craniotomy. An external ventricular drainage catheter was placed in the same session if there was concomitant hydrocephalus. Although craniotomy is the most important surgical interventional method, stereotactic thrombolysis and aspiration in addition to endoscopic methods are also used (12,13,14). Fu C et al. have emphasized the superiority of endoscopic intervention as regards the final surgical and clinical results in basal ganglion hemorrhages (15).

Despite prompt surgery, all of the patients died during the intensive care process. Although this rate seems to be higher than in the general literature, it is correlated with the 'intracerebral hemorrhage score'. We believe that this score constitutes the most important factor for determining the prognosis and also acts as a partial guideline when determining the surgical indication.

CONCLUSION

Although surgery is still the preferred treatment method for hematomas 4 cm and more in size orginatingfrombasalganglia, the pathology is associated with a high mortality rate. It is difficult to make a general judgment about choosing between a surgical or conservative approach. Each patient should be evaluated individually. However, acting more selectively may be an appropriate approach for the surgical decision. We would like to make it clear that we have doubts about the benefit of surgery in cases with advanced age, comorbid systemic disorders, a deep localized hemorrhage, anticoagulant use, or preoperative low GCS.

REFERENCES

1. Vespa PM, Martin N, Zuccarello M, AwadI, Hanley DF. Surgical trials in intracerebral hemorrhage.Stroke 2013; 44(6): 79–82.
2. Broderick J, Brott T, Duldner J, Tomsick T, Huster G. Volume of intracerebral hemorrhage. A powerful and easy-to-use predictor of 30-day mortality. Stroke 1993; 24(7): 987–93.
3. ProvencioJJ, Da SI, MannoEM. Intracerebral hemorrhage: new challenges and steps forward.NeurosurgClin N Am 2013; 24(3): 349–59.
4. Poon MT, Fonville AF, Al-Shahi SR. Long-term prognosis after intracerebral haemorrhage: systematic review and meta-analysis. J Neurol Neurosurg Psychiatry 2014; 85(6): 660–7.
5. Cordonnier C, DemchukA, Ziai W, Anderson CS. Intracerebral haemorrhage: current approaches to acute management.Lancet 2018; 392(6): 1257-68.
6. Juvela S, Kase CS. Advances in intracerebral hemorrhage management. Stroke 2006; 37(2): 301-4.
7. Zuccarello M, Brott T, Derex L, Kothari R, Sauerbeck L, Tew J. Early surgical treatment for supratentorial intracerebral hemorrhage: a randomized feasibility study. Stroke 1999; 30(9): 1833-9.
8. Fernandes HM, Gregson B, Siddique S, Mendelow AD. Surgery in intracerebral hemorrhage. The uncertainty continues. Stroke 2000; 31(10): 2511-6.
9. Godoy DA, Nunez-Patino RA, Zorrilla-Vaca A, Ziai WC, Hemphill JC. Intracranial hypertension after spontaneous intracerebral hemorrhage: A systematic review and meta-analysis of prevalence and mortality rate. Neurocrit Care 2019; 31(1): 176-87.
10. Chen CJ, Ding D, Ironside N, Buell TJ, Southerland AM, Woo D et al. Predictors of surgical intervention in patients with spontaneous intracerebral hemorrhage. World Neurosurg 2019; 123(3): 700-8.
11. Luzzi S, Elia A, Del Maestro M, Morotti A, Elbabaa SK, Cavallini A et al. Indication, timing and surgical treatment of spontaneous intracerebral hemorrhage: systematic review and proposal of a management algorithm. World Neurosurg2019; 124(4): 769-78.
12. Sirh S, Park HR.Optimal surgical timing of aspiration for a spontaneous supratentorial intracerebral hemorrhage.J Cerebrovasc Endovasc Neurosurg 2018; 20(2): 96-105.
13. Bhatia K, Hepburn M, Ziu E, Siddiq F, Quereshi AL. Modern approaches to evacuating intracerebral hemorrhage. Curr Cardiol Rep 2018; 20(12): 132.
14. Hersh EH, Gologorsky Y, Chartrain AG, Mocco J, Kellner CP. Minimally invasive surgery for intracerebral hemorrhage. Curr Neurol Neurosci Rep 2018; 18(6): 34.

15. Fu C, Wang N, Chen B, Wang P, Chen H, Liu W et al. Surgical management of moderate basal ganglia intracerebral hemorrhage: comparison of safety and efficacy of endoscopic surgery, minimally invasive puncture and drainage and craniotomy. World Neurosurg 2019; 122(2): 995-1001.

Sorumlu yazar

Hakan YILMAZ(Uzm Dr)
Sağlık Bilimleri Üniversitesi, İzmir Bozyaka Eğitim ve Araştırma Hastanesi, Nöroşirürji Kliniği, İzmir
Tel: 0 5066211829
E -posta: dr_hakanyilmaz@hotmail.com
ORCID: 0000-0002-2180-1195

Ümit KOCAMAN (Uzm Dr) ORCID: 0000-0002-9599-0013